

Variability in Nerve Location During da Vinci[®] Prostatectomy

R. Kuhn

Abstract

Objectives

Preservation of nerves during da Vinci prostatectomy (dVP) has been clinically proven to be critical to preservation of urinary function and surgeon perception has been shown to be a poor predictor of nerve location during dVP. Despite this evidence, opinions still vary on the ability of surgeons to use anatomic landmarks to accurately identify these nerves during dVP and to predictably preserve urinary function.

To explore the location of these critical nerves compared to anatomic landmarks and quantify the amount of variability, a single surgeon performed intraoperative nerve identification using the ProPep Nerve Monitoring System™ on a series of consecutive patients undergoing dVP.

Methods

The ProPep Nerve Monitoring System was used to identify the superficial portion of the perineal branch of the pudendal nerve (PBPN) in real time during dVP. The PBPN has been shown to innervate the levator ani (LA) and external urethral sphincter and to be a critical nerve in the maintenance of urinary continence. A low level electric current (0.5-10 milliamps) similar to that used for nerve identification in other surgical specialties was applied to the tissues during prostate dissection and the resulting waveforms allowed the surgeon to identify the exact location of the PBPN. The surgeon documented the location of the nerve relative to the prostate using a clock-face reference on both the right and left sides. The surgeon also documented the distance of the nerve from the prostate on both the right and left sides. Data was collected prospectively.

Results

The ProPep Nerve Monitoring System reliably identified the otherwise invisible PBPN with an evoked electromyographic (e-EMG) waveform in 100% of the patients. Using a clock-face reference with 12 o'clock being located at the most anterior aspect of the prostate, and 6 o'clock at the most posterior aspect, the nerve on the left side was located at 7:30 50% of the time, 8:00 25% of the time, 7:00 13% of the time, and 6:30 12% of the time. On the right side, the nerve was located at 4:30 50% of the time, 4:00 25% of the time, 5:00 13% of the time, and 5:30 12% of the time. Distance of the nerve from the prostate also varied with the nerve being located 3mm from the prostate 45% of the time, 2mm from the prostate 18% of the time, 4mm from the prostate 18% of the time, 8mm from the prostate 9.5% of the time, and 1mm from the prostate 9.5% of the time.

Conclusions

The use of the ProPep Nerve Monitoring System during dVP identified the otherwise invisible PBPN which innervates the pelvic floor in 100% of the cases. Both the nerve location relative to the prostate as well as the nerve distance from the prostate varied from case to case with the most common location occurring only 50% of the time. Given the importance of nerve preservation for urinary control recovery, the documented inability for surgeon perception to predict nerve location, and the documented variability of nerve location from case to case, the use of the ProPep Nerve Monitoring System is an effective tool for improving the accuracy of nerve identification and could improve the preservation of these nerves and the clinical outcomes achieved by patients.

Background

Intraoperative neurophysiologic monitoring (IOM) is a technique that uses electrophysiological stimulation and recording to provide surgeons with real-time information regarding the location of nerve tissue and the functional integrity of the nervous system during an operation. Such recordings are standard of care in many orthopedic, neurosurgical, and vascular surgical cases. Published data has shown that IOM helps reduce the incidence of permanent neurologic deficits, and in some types of operations, can also help to achieve the therapeutic goal of the operation.

Intraoperative monitoring of motor nerves is usually done by recording e-EMG potentials from the muscles that these nerves innervate. Recording of such e-EMG potentials can be helpful in identifying neural structures in cases where the nerve anatomy is not visible to the surgeon or where normal anatomy has been altered by tumors or malformations.

It has only been with the recent development of the ProPep Nerve Monitoring System by ProPep Surgical® that IOM has been able to be successfully used in laparoscopic pelvic surgery where nerve identification and preservation continued to rely solely on the judgment of individual surgeons. This new nerve monitoring system has overcome the previous obstacles of deficiencies in e-EMG technology sophistication and the inability to access the closed abdominal space with nerve monitoring equipment. Furthermore, the ProPep Nerve Monitoring System takes advantage of the fact that much pelvic surgery is now performed using robotics, and has developed a platform that interfaces with the robotic surgical system providing its informational outputs directly into the surgeon's visual field.

Specific to dVP, published literature has shown that inadvertent injury to the nerves innervating the levator ani (LA) and external urethral sphincter, which play an important role in urinary continence, can result in atrophy of these muscles and increased incontinence.⁶ Conversely, it has also been shown that successful, selective preservation of the nerves to these muscles results in more rapid return of urinary continence.⁵

Surgeons currently performing dVP, laparoscopic, and open radical prostatectomy use surgically identified anatomy to make intra-operative decisions regarding what tissue to preserve to avoid unwanted injury to the nerves innervating the LA and external urinary sphincter. However, published literature has shown that the course of the nerves around the prostate do not always agree with surgically identified anatomy and the use of these landmarks has led to inconsistencies in outcomes.³

With the documented success of using IOM to provide surgeons with real-time information about nerve location in other specialties, and the known variability in outcomes using anatomic landmarks to identify the location of nerve tissue during dVP, the possibility exists that variability in nerve location is responsible for this variability in outcome. Furthermore, the ProPep Nerve Monitoring System may offer a real-time solution for documenting the location of these nerves during dVP.

Methods

The ProPep Nerve Monitoring System was used to identify the nerves innervating the LA and external urethral sphincter in real-time during dVP. A cannula introducer (figure 1) was used to deliver insulated, monopolar electrodes into the closed abdominal cavity during dVP in a way that did not affect the pneumoperitoneum and did not interfere with the performance of the surgical dissection. Once inside the abdominal cavity, the two electrodes were placed into the LA muscle proximal to the external urethral sphincter on either side of the prostate (figure 2) and a ground electrode was placed into the external abdominal wall.

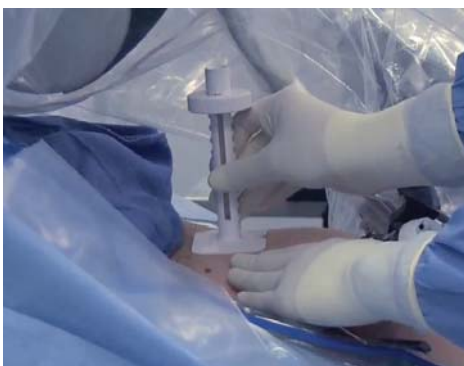

Figure 1

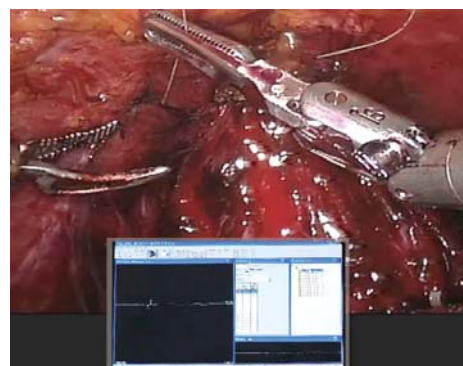


Figure 2

The ProPep Nerve Monitoring System was then used to deliver a low current (0.5-10 milliamps) stimulation signal to these pelvic nerves using the da Vinci Maryland bipolar instrument during prostate dissection and the resulting waveforms (figure 3) allowed the surgeon to identify the exact location of the PBP. By transmitting the stimulation signal through the Maryland bipolar instrument, the surgeon was able to continue the operation uninterrupted and simply touch the tissue he was handling with the bipolar instrument after switching the instrument to stimulation mode using a foot pedal. When the tissue in question was touched with the bipolar, the stimulation signal was sent through the tissue and returned to the ProPep Nerve Monitoring System through the previously placed monopolar electrodes. The system then instantly analyzed the signal through a series of electronic filters and if the tissue being touched was close to the nerves innervating the LA and external urethral sphincter, a standard compound motor action potential was seen on the computer monitor (figure 3) and transmitted to the surgeon's visual field via the picture-in-picture capabilities of the da Vinci Surgical System (figure 2). This allowed the surgeon to receive this information without having to distract his attention from the surgical field. As the stimulating bipolar instrument progressed closer to the nerve, the waveform amplitude increased. The information provided to the surgeon using this technology was therefore not static but instead was used as an ongoing communication throughout the dissection so the surgeon was aware of trends and dynamic changes as the operation progressed. At the location of maximum waveform amplitude, the location of the nerve relative to a clock face, and its distance from the prostate were recorded by the surgeon for both the right and left side. This data was collected prospectively for a consecutive series of patients.




Figure 3

Results

The use of the ProPep Nerve Monitoring System was safe, resulting in no complications and efficient, adding no significant time to the surgical procedure. Furthermore, using this system, the surgeon was able to reliably identify the otherwise invisible PBP with an e-EMG waveform in 100% of the patients. Using a clock-face reference with 12 o'clock being located at the most anterior aspect of the prostate, and 6 o'clock at the most posterior aspect, the nerve on the left side was located at 7:30 50% of the time, 8:00 25% of the time, 7:00 13% of the time, and 6:30 12% of the time (figure 4). On the right side, the nerve was located at 4:30 50% of the time, 4:00 25% of the time, 5:00 13% of the time, and 5:30 12% of the time (figure 5).

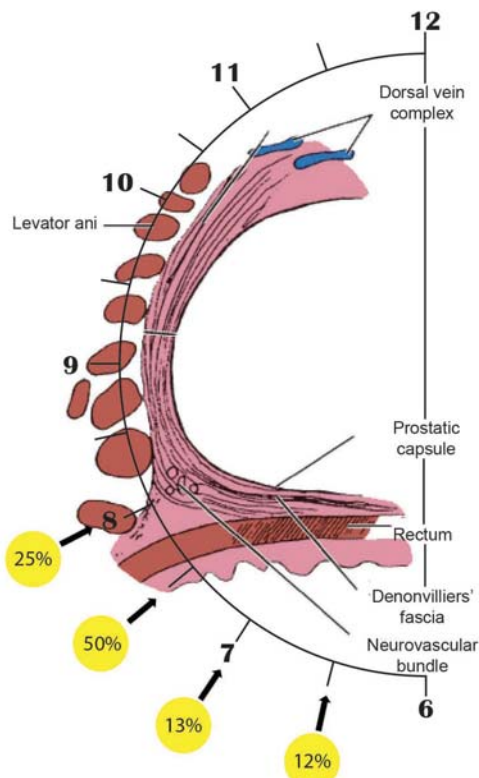


Figure 4

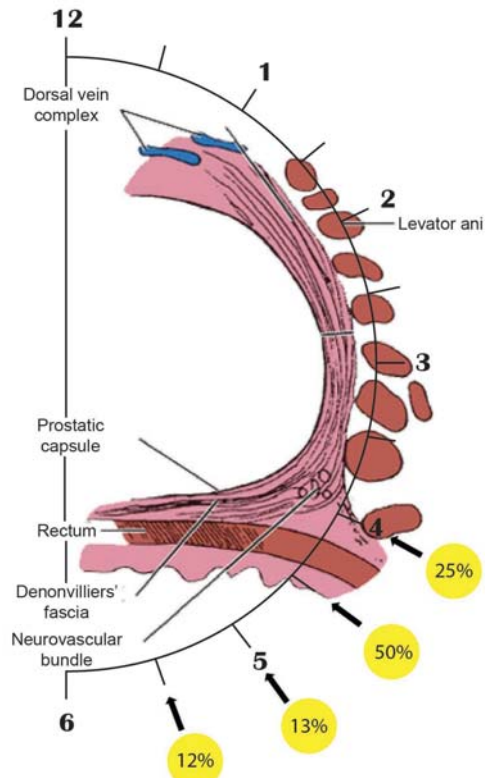


Figure 5

Distance of the nerve from the prostate also varied with the nerve being located 3mm from the prostate 45% of the time, 2mm from the prostate 18% of the time, 4mm from the prostate 18% of the time, 8mm from the prostate 9.5% of the time, and 1mm from the prostate 9.5% of the time (figure 6).

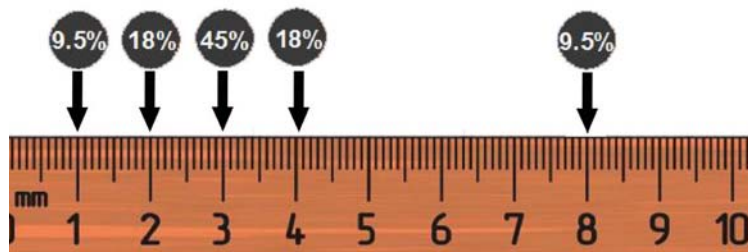


Figure 6

Conclusions

The use of the ProPep Nerve Monitoring System during dVP was safe and efficient. It allowed the surgeon to identify the otherwise invisible PBPN which innervates the pelvic floor in 100% of the cases. Both the nerve location relative to the prostate as well as the nerve distance from the prostate varied from case to case with the most common location occurring only 50% of the time. Given the importance of nerve preservation for urinary control recovery, the documented inability for surgeon perception to predict nerve location, and the documented variability of nerve location from case to case, the use of the ProPep Nerve Monitoring System is an effective tool for improving the accuracy of nerve identification and could improve the preservation of these nerves and the clinical outcomes achieved by patients. Given the documented variability in nerve location, it is the Author's belief that further studies are warranted to determine the full benefits to surgeons and patients when this technology is utilized.

Discussion

The use of this technology is obviously not a replacement for surgeon judgment. The surgeon still needs to understand anatomy as well as what surgical and non-surgical factors can affect the response to the stimulation and based on this knowledge decide whether the information provided should result in operative modification. For example, muscle relaxants should not be used during this portion of the procedure and any short acting relaxants should be reversed in advance of anticipated nerve stimulation. Additionally, the surgeon must be aware that a false positive response can be obtained if the surgeon directly stimulates the muscle and a false negative response can occur if the area being tested is fully submerged in fluid (urine, blood, irrigation fluid), or if the patient is paralyzed in which case the muscle cannot respond to the stimulation current. It is also important for the surgeon to understand that, medical conditions like diabetes, advanced patient age, tissue ischemia and mechanical insult can all result in a decrease in the number of nerve fibers firing. From an electrophysiological point of view, these factors could result in a reduction in the amplitude, an increase in the latency, an overall change in the morphology of a waveform, or a complete absence of the waveform. The surgeon must be aware of these factors and consider them when interpreting the signal received during IOM.

References

1. Sekiya T, Moller AR: Cochlear nerve injuries caused by cerebellopontine angle manipulations. An electrophysiological and morphological study in dogs. *J Neurosurg* 67:244-249, 1987.
2. Sekiya T, Moller AR: Avulsion rupture of the internal auditory artery during operations in the cerebellopontine angle: A study in monkeys. *Neurosurgery* 21: 631-637, 1987.
3. Takenaka et al. "pelvic autonomic nerve mapping around the prostate by intraoperative electrical stimulation with simultaneous measurement of intracavernous and inraurethral pressure." *JUrology* January 2007; Vol 177, 225-229.
4. Wallner C, van Wissen J, Maas CP, Dabhoiwala NF, DeRuijter MC, Lamers WH. Department of Anatomy and Embryology, Academic Medical Center, University of Amsterdam, Amsterdam, The Netherlands. The contribution of the levator ani nerve and the pudendal nerve to the innervation of the levator ani muscles; a study in human fetuses. *Eur Urol* Nov 2008; 54(5):1143-4.
5. Robert S Hollabaugh Jr, Roger R Dmochowski, Timothy G Kneiba, Mitchell S Steinera. Urology Preservation of Putative Continence Nerves during Radical Retropubic Prostatectomy Leads to More Rapid Return of Urinary Continence. *Urology* June 1998; Volume 51, Issue 6 , Pages 960-967.
6. Lisa M. Pierce, DSc, Kimberly W. Coates, MD, Lori A. Kramer, MD, Jason C. Bradford, MD, Karl B. Thor, PhD, Thomas J. Kuehl, PhD. Effects of bilateral levator ani nerve injury on pelvic support in the female squirrel monkey. Presented at the 28th Annual Scientific Meeting of the American Urogynecologic Society, Hollywood, FL. Sept. 27-29, 2007.
7. Robert S Hollabaugh Jr, Roger R Dmochowski, Timothy G Kneiba, Mitchell S Steinera. Preservation of Putative Continence Nerves during Radical Retropubic Prostatectomy Leads to More Rapid Return of Urinary Continence. *Urology* 16 February 1998.
8. TAKENAKA Atsushi¹, HARA Ryohei¹, SOGA Hideo², MURAKAMI Gen³, FUJISAWA Masato¹. (1) Department of Urology Kawasaki Medical School, JAPAN, (2) Department of Kawachi General Hospital, JAPAN, (3) Department of Anatomy, Sapporo Medical University School of Medicine, JAPAN. A novel technique for approaching the endopelvic fascia in retropubic radical prostatectomy, based on an anatomical study of fixed and fresh cadavers. *British Journal of Urology* 2005; vol. 95, no6, pp. 766-771.
9. Lu-Jie Song¹, Hong-Kai Lu², Jin-Ping Wang³, Yue-Min Xu¹. (1) Department of Urology, Affiliated Sixth People's Hospital, Shanghai Jiaotong University, Shanghai, China, (2) Department of Urology, Weifang Traditional Chinese Medicine Hospital, Shandong, China, (3) Department of Anatomy, Weifang Medical College, Shandong, China. Cadaveric study of nerves supplying the membranous urethra. *Neurourology and Urodynamics* April 2010; Volume 29, Issue 4, pp. 592-595.



For more information on the ProPep Nerve Monitoring System,
contact ProPep Surgical:

11614 Bee Caves Road
Suite 220
Austin, TX 78738
(512) 617-6740
ProPepSurgical.com